

# **Neuro-biofeedback Imaging in Human Performance and Mental Health**

Thomas F. Collura, Ph.D., QEEG-D, BCN, LPC

BrainMaster Technologies, Inc., and the Brain Enrichment Center, Bedford, OH

September 4, 2014 – Submitted to NeuroConnections

There is increasing awareness of the importance of brain health and brain fitness for individual well-being, as well as for the strength of societies and civilizations. A significant amount of time and expense are devoted to reducing mental and emotional distresses, and also to improve performance in academic, sports, and related pursuits. An additional important aspect is the effect of stress or trauma on individual health, and the disorders that can result from excess stress. It is clear that neuroscience holds great potential as a resource for mental health practitioners who want to help clients at a fundamental level.

It is not hard to imagine a practitioner thinking, “if I only knew what was going on inside my client’s head.” There are limits to what can be gained from behavioral observations, self-report, and other information available to those who must evaluate and treat mental, emotional, or behavioral concerns. The value of self-report can be compromised by limitations in the client’s awareness, honesty, confidence, and ability to express sensitive concerns. Behavioral observations provide objective data, but do not necessarily allow one to determine why an individual chooses (or does not choose) certain behaviors. For example, it may not be clear whether an issue is based primarily on being excessively activated or driven, as opposed to having insufficient inhibitory control, or a combination of these. In short, the information available has limited ability to reveal what is going on internally, and functionally, in a client’s brain at any particular moment. However, this type of information is essential, if therapists are to understand clients and interact with clients in a meaningful and fruitful manner.

Until very recently, the field of neuroimaging had little direct relevance or impact on the field of clinical mental health. The cost of equipment such as MRI, fMRI, CT, or PET generally exceeds the million dollar mark, and the facilities and staff necessary to provide imaging services have put diagnostic and evaluative use in the range of \$1000 or more per visit. Moreover, these modalities, while of interest in research and academic settings, are impractical for use in all but the most well equipped (and endowed) hospitals and universities. This situation has changed, however, with the availability of low-cost, high-speed EEG-based imaging methods. Various methods exist for recovering data related to localized brain activity based upon surface EEG recordings, operating in real time, and useful for assessment as well as for treatment modalities.

EEG begets QEEG begets Neurobiofeedback begets live brain activation imaging.

It is now possible to identify a new modality that can be called “NeuroBiofeedback Imaging” or NBI. NBI is produced by computing (reconstructing) a sufficient number of volume elements

("voxels") based upon surface EEG measurements, and rendering them on a display. In order to produce a useful NBI image, it is necessary to produce a large number of voxels. The more voxels that can be produced, the better the image. Until the development of low-resolution electromagnetic tomography (LORETA), this was not possible. The basic LORETA implementation provides over 2,000 voxels. A more advanced version, "standardized LORETA" or sLORETA, provides over 6,000 voxels. In the implementation described here, each voxel is converted into a precise amplitude, and colored in the image, to provide a full-color, live, 3-dimensional animation of brain activity.

Based upon the last decade of developments, it has become possible to merge system functions that had previously been not only difficult or expensive to implement in isolation, but also to combine methods. In the 1980's an EEG system could easily cost \$20,000 or more. Computerized QEEG systems at that time were few, and cost between \$50,000 and \$100,000. Early 1-channel neurofeedback systems at that time were typically in the \$10,000+ range. Therefore, to simply acquire an EEG, a QEEG, and a neurofeedback system, one would have to invest more than a home, or Maserati, cost. None of these systems would offer true brain imaging, which at those times required \$1,000,000+ CT, MRI, or MEG type equipment. Today, it is possible, for less than \$20,000, to acquire a system that provides not only EEG and QEEG, but also database-referenced live neurofeedback. More recently, advances in computer hardware and software have made it possible to achieve reconstruction of a brain image comprising over 6,000 volume elements ("voxels"), and to create brain images in real time.

In the images shown here, when voxels are presented in the form of statistical z-scores, the database used is BrainDX (John, Prichep, & Easton, 1987; <http://www.braindx.net>), which is based upon the original NXLink database from New York University. This database has been extended, and supplemented with not only surface EEG z-scores, but also sLORETA voxel z-scores. This makes it possible to convert every voxel into a z-score. This shows the level of brain activity in comparison to a typical individual at rest (eyes open or eyes closed). When voxels appear in green, that is a neutral z-score, meaning the level of activity is typical. Orange and red correspond to higher levels of activity, and blue corresponds to a lower level of activity.

The activity levels are computed for each frequency component band and must be interpreted as such. For example, elevated levels of alpha indicate that the brain area is in fact at rest, in an idling or background state. Elevated theta indicates an extreme state of relaxation, and either inactivity, or internally-directed activity, such as thinking or creative imaging. We have begun to use gamma (35-45 Hz) for imaging, because it provides an accurate and rapid indication of activation in this band, which reflects overt processing and integration of information. Gamma imaging using z-scores presents a new capability in brain imaging.

When EEG, QEEG, neurofeedback, and live brain imaging are combined into a practice model, they can provide an integrated approach to client evaluation, assessment, and providing mental health-related services. Based on neuroscientific principles, it is possible to identify both

strengths and weaknesses in brain functional patterns, and to relate these to behavioral and self-report data. Because brain regions have been identified with particular functions and sets of functions, an approach to functional evaluation that looks for location-specific regulatory patterns can be clinically useful. In the examples that follow, it will be seen that cognitive, emotional, and behavioral capacities and limitations can be effectively imaged and observed, as if a virtual window into brain function has been opened.

QEEG-based neurobiofeedback imaging is based upon the data acquired from surface electrodes, generally using the standard 10-20 sites. A portion of EEG is then selected for further analysis, including imaging using standardized low-resolution electromagnetic tomography (sLORETA, Pascual-Marqui, 2002). The following figure shows an example of an EEG signal with a section highlighted for further analysis

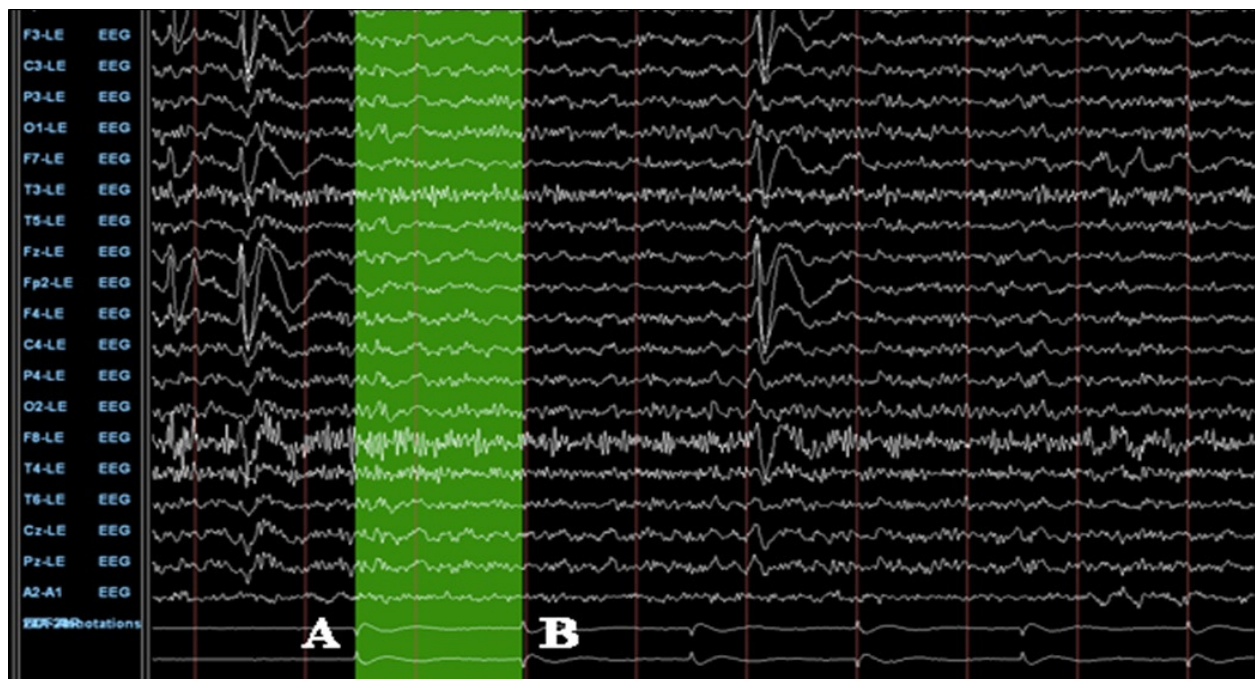


Figure 1 – a typical display of an EEG recording from the scalp, along with markings that show the exact time interval that will be analyzed and imaged.

### Z-Score Imaging emerges

When analyzing EEG patterns, one method of determining how to describe the activity is to reference the data to a standard, so that we can immediately see how the brain differs from a “typical” brain. By typical, we generally mean a brain that is not active, not under task, and not experiencing any disorders or dysregulations.

Z-Score imaging is a new method, in which each and every one of the thousands of volume elements (“voxels”) is instantly converted into a color that reflects its level of activation. The units that are being quantified relate to the amount of electrical current estimated to be occurring

in that voxel. The units are expressed as “current source density,” which is the amount of current per unit of volume. They are in units of “nanoamperes per cubic millimeter.” The voxels thus become image components, and the activity of the brain can be built up by combining the voxels on a real-time display. This representation provides a 3-dimensional representation that can be rotated, zoomed, or modified to show only specific regions of interest (ROI’s), Brodmann areas, or even networks and hubs.

The following figure, for example, shows the brain regions that were identified and numbered by Brodmann, and which are used today. As it turns out, because the areas were first identified with the cytoarchitectonic structure of the cells, they naturally identify locations that are functionally similar, and thus produce useful functional divisions of the brain.

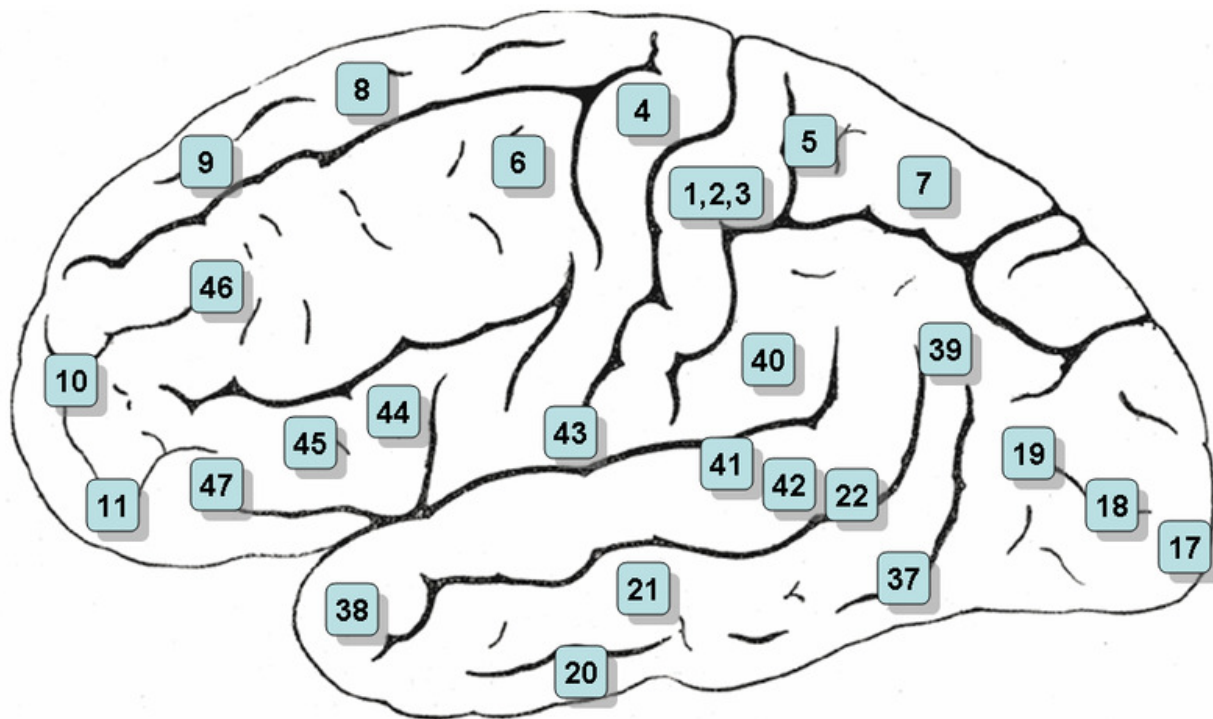


Figure 2 - the Brodmann areas of the brain, shown on a left lateral view. The frontal lobes (e.g. areas 10 and 11) are on the left, and the occipital lobes (e.g. areas 17 and 18) are on the right.

By using NBI in an event-related manner, a new modality emerges. This can be referred to as “Event-Related NeuroBiofeedback Imaging.”

The following shows an example of an sLORETA-generated brain activation image. In this and other such images, the 3-dimensional volume elements (voxels) are 5mm in size, and represent the estimated amount of neuronal activity within each voxel. The image can be viewed, modified, and rotated by the user, providing a view of the brain that best shows important activity (or inactivity). This type of display includes identifying information so that the data can be interpreted for research or for clinical use. Because the images are instantaneous, it is important to know the exact moment that the image reflects. This is a snapshot of brain activity that contains accurate and high-speed information about which locations in the brain are active and at which exact time.

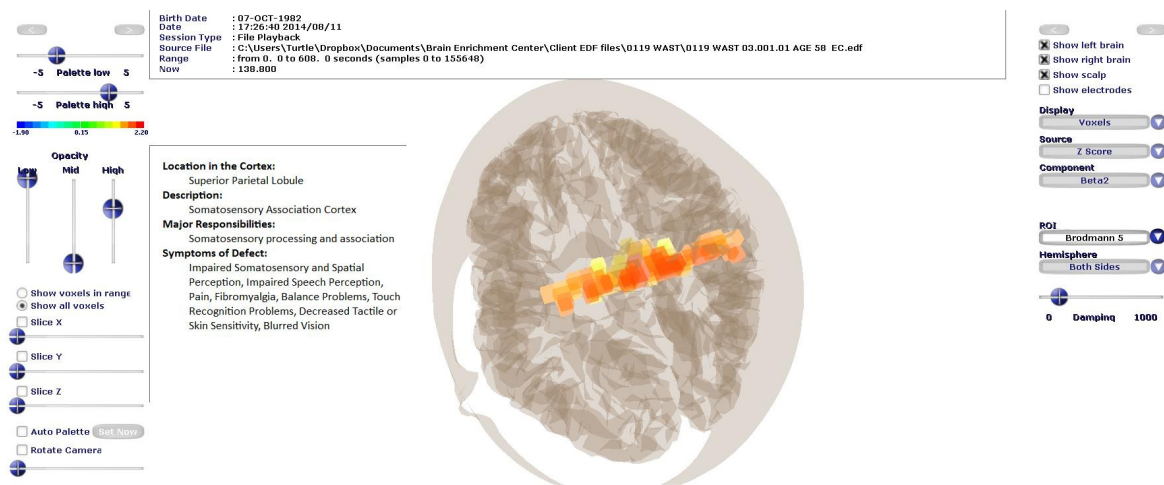


Figure 3 – a typical 3-D image of brain activation, showing the exact regions involved.

While this type of live neuroimaging may seem new to the mental health field, it draws upon over a century of science and clinical experience that underly its use. The concept of localized brain function was established in the earliest years of clinical neuroscience, dating to Jackson, Brodmann, Broca, Wernike, and other pioneers whose names remain fundamental in clinical and experimental neuroscience.

Even a modern fMRI can only produce one image in about 5 to 8 seconds. BrainAvatar QEEG-based imaging, on the other hand, working with instantaneous brain electrical data, can produce an image in less than 1/30 of a second. Thus, not only can high resolution accurate brain electrical images be produced in real time, it is further possible to produce brain animations, which are movies that show brain activity as it happens, and reveal details of how the brain actually functions.

The difference between a static brain image and a live brain animation is like the difference between a photograph of a golfer, versus watching the golfer in action. The summary data

resembles the score at the end of a match, whereas a live rendition can be used to see the details and dynamics of how the individual actually processes cognitive and emotional data, and approaches and performs tasks.

When live brain imaging is combined with neurofeedback, an entirely new method emerges. Traditionally, biofeedback and neurofeedback displays consist of screens with images, animations, games, or other renderings that attempt to relay the brain information to the client. Some displays may show a brain or similar image, but none of them provide accurate, instantaneous information related to the precise localized activity in the brain at any instant.

It is one thing to draw a picture of a brain, and to add markers or other indicators to show the trainee what is happening. It is another thing entirely to construct the entire image, piece by piece, from detailed brain activation data. Not everyone's brain is the same, and precise locations will vary from individual to individual. Therefore, the ability to accurately estimate the activity in many small volumes at once is the key to rendering a detailed, precise, and accurate image of brain activation. This then becomes the ideal neurofeedback display, capable of replacing all others, both for assessment and evaluation, and for training and therapy.

The importance of flexibility and appropriateness

A key concept in modern neuroscience is that brains alternate between states of activation and states of rest. Serman (1996) and Lubar (1997) have described the processes by which the brain self-regulates its internal rhythms. While this would seem to be a simple concept, one of the first important experimental demonstrations of this was by Serman et al. ( ). They discovered that when pilots were performing at maximal speed and effectiveness, they exhibited the ability to shift from a concentration (beta) state into a relaxed (alpha) state as the task demanded.

The following figure shows the relationship between the states of concentration and relaxation, along a continuum. Based on this principle, we understand that any particular region of the brain, while it may produce more than one rhythm at a time, can be identified with being primarily in one region of this graph at any moment.

It is a basic fact that no system has infinite resources to draw upon. Therefore, at any time, any system, or part of a system, will have to be predominantly in one state or another, and cannot do "everything at once." Depending on the state of a brain region, it will tend to be more or less activated, which is a reflection of its local conditions. It is also true that in order for a system to be functional and flexible, its parts must undergo state transitions, during which regions that are at rest may become activated, or vice versa. Generally, if any system or part of a system gets "stuck" and cannot adjust its level of activation, the system will not be able to function well. This is true whether the system is stuck in a low-frequency, relaxed mode, or whether it is stuck in a high-frequency, concentrated mode. Being stuck in any particular activation pattern is a problem, whether it is high or low.

The brain is a multicomponent system, that operates by recruiting resources (regions or networks), using them, and then releasing them. In order to perform different tasks such as reading, building, thinking, or searching, the brain brings together the regions that must work together into subsystems for that task, and then releases or decouples those subsystems when they are no longer needed. For example, an individual who shifts attention from one external stimulus to another must first release the resources that are attending to the first stimulus, then organize and make a decision to switch to another stimulus, and finally organize the brain once again, to carry out the focus on the new stimulus (or task). Being stuck on one task is essentially the same as not being able to get on task, as far as overall efficiency and flexibility are concerned.

EEG-based brain data and images are particularly valuable in the context of this model. Other imaging techniques such as CT, MRI, fMRI, and PET are based on anatomic, metabolic, or related physical processes. Only the EEG is based solely on the electrical activity of the brain. EEG reflects the activity of the working cells in the cerebral cortex known as “pyramidal cells.” When these cells, which are engaged in the information processing and emotional control of the brain are active, they produce signals that are measurable from the scalp. It is these signals that are used in EEG-based neurobiofeedback imaging. Therefore, these images truly reflect the activity of the brain, and ways that other methods cannot (Sanders, 2014).

In addition to being based on the relevant electrical activity of the brain, EEG-based imaging has been validated in comparison to other imaging techniques, and has been shown to provide a valid and accurate localization of brain activity (Ikeda & Kirino, 2004; Xiaoxiao, Towle, He, & He, 2007).

Underlying Brain Rhythms – the Cycle of Concentration and Relaxation

## The Concentration/Relaxation Cycle and EEG Amplitude/Frequency Changes

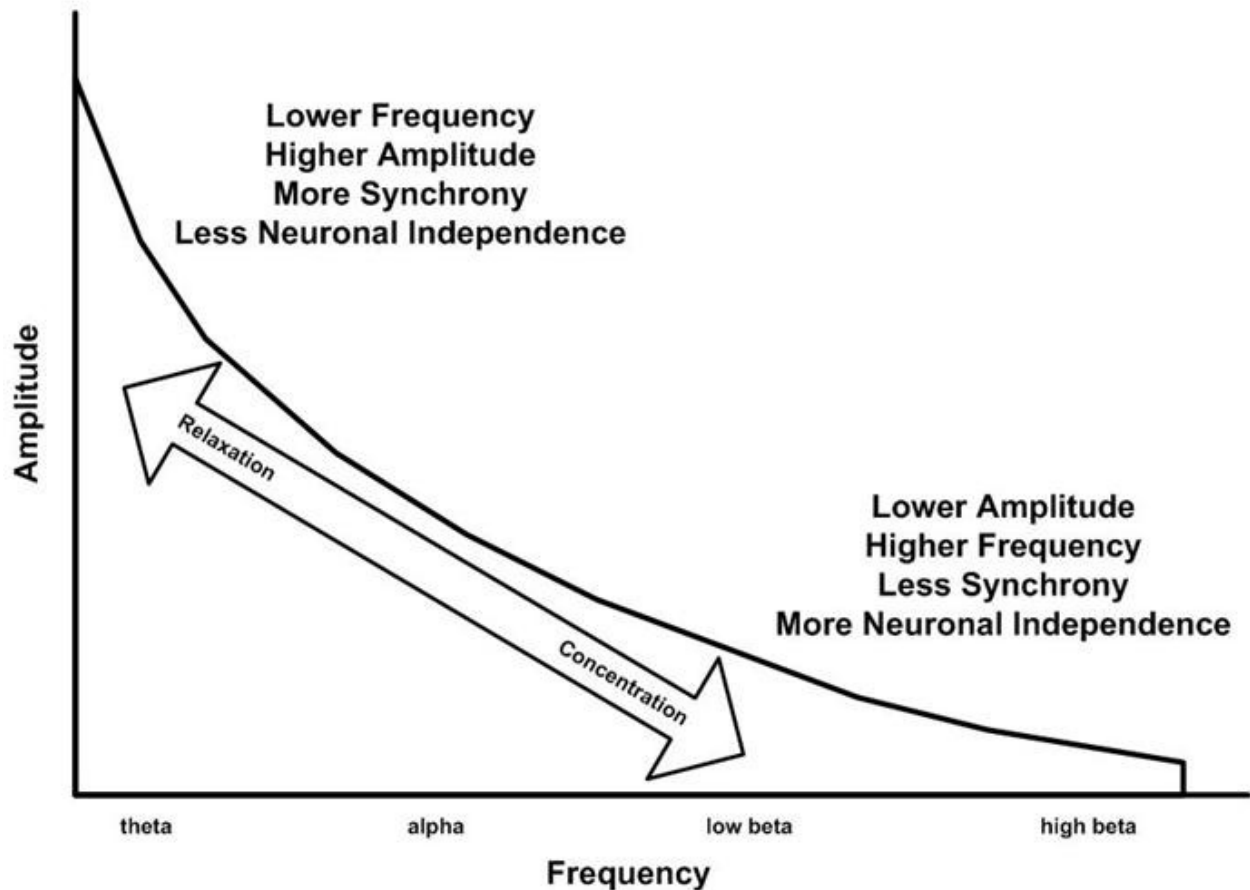


Figure 4 – The Concentration/Relaxation Cycle for brain (cortical) activation.

### Neurobiofeedback Imaging and Human Performance

By combining the concepts of EEG-based brain activation imaging with an activation/relaxation model of brain activity, it is possible to analyze and interpret brain images in specific situations, and with particular individuals. These may be clients, but they may also be peak performers or other individuals in specific situations.

In a recent project, a team including a QEEG imaging specialist and a physiological monitoring technologist was brought together on a remote Nevada track, to study the brains of people driving the newest model Corvette Stingray. This was sponsored by General Motors, as part of a “reverse test drive.” The concept behind this project was that, by studying the brains and bodies



of people driving the vehicle, their reactions could be quantified and understood. This was found to be true, and individual results were very revealing for each participant.

One of the most important lessons we learned with the Corvette Team was that EEG's change when people are active, apprehensive, or relieved. An EEG pattern that might be interpreted as abnormal or dysregulated in a resting condition could be quite adaptive and beneficial under stress or demand.



Figure 5 – a live installation in which EEG imaging is being used to assess the performance of individuals in a real-world task situation. This was taken at a race track in Nevada, during a test of high-performance sports car driving.

#### Craig - A Precision Driver

Craig is a precision driver, who is among the best in his field. He receives up to 10,000 per day to plan, orchestrate, and drive in difficult scenes such as are used in commercials and motion pictures. He is capable of repeatedly driving in an exactly precise manner, at high speeds and including difficult maneuvers, jumps, and even crashes. While Craig is driving, he exhibits a notable pattern that suggests that he is preferentially activating the visual, sensory integration, and motor areas, while reducing activity in his frontal executive, memory, or planning areas. This suggests that he has mastered the ability to automatically work with his sensory and motor systems without overthinking tasks. This is analogous to the beta state noted by Serman et al. in situations in which skilled aviators were also performing a difficult and precise task.

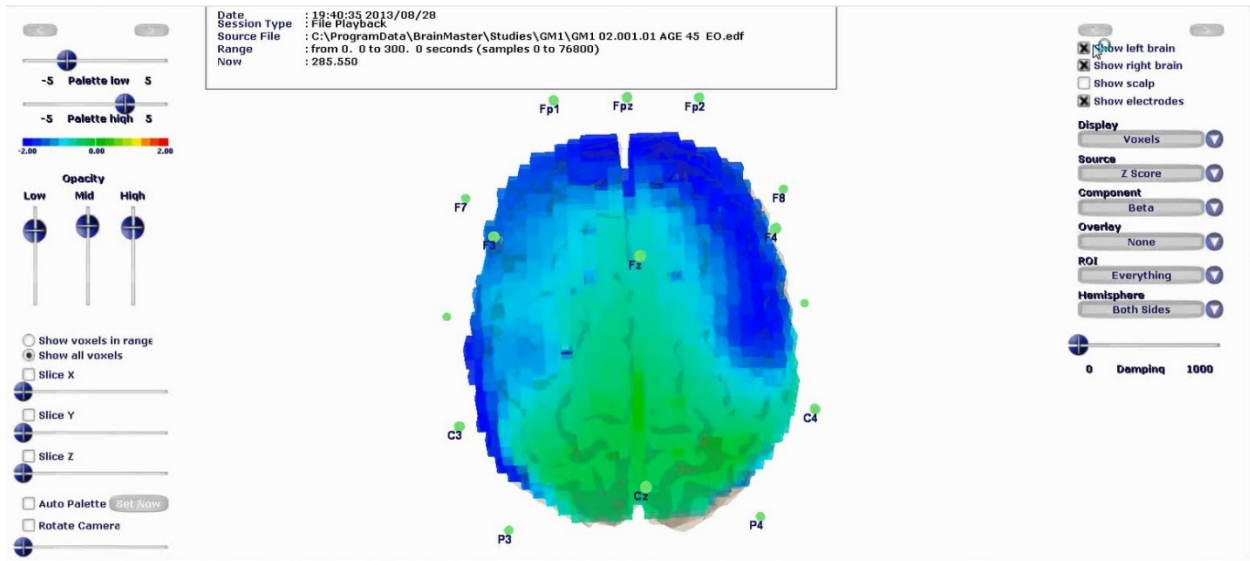


Figure 6 – the EEG activation pattern (beta) of an experienced, precision race car driver. It is evident that the brain is not highly emotionally charged, but that resources are being focused on the visual and motor systems.

Later, after completing the drive, Craig’s brain transitioned into a state of extreme alpha, particularly in the same regions that had previously been activated. This is an example of what Sterman referred to as post-reinforcement synchronization (PRS). In this example, the EEG signal is superimposed with the image, to show the size and symmetry of the alpha bursts that make up the PRS.

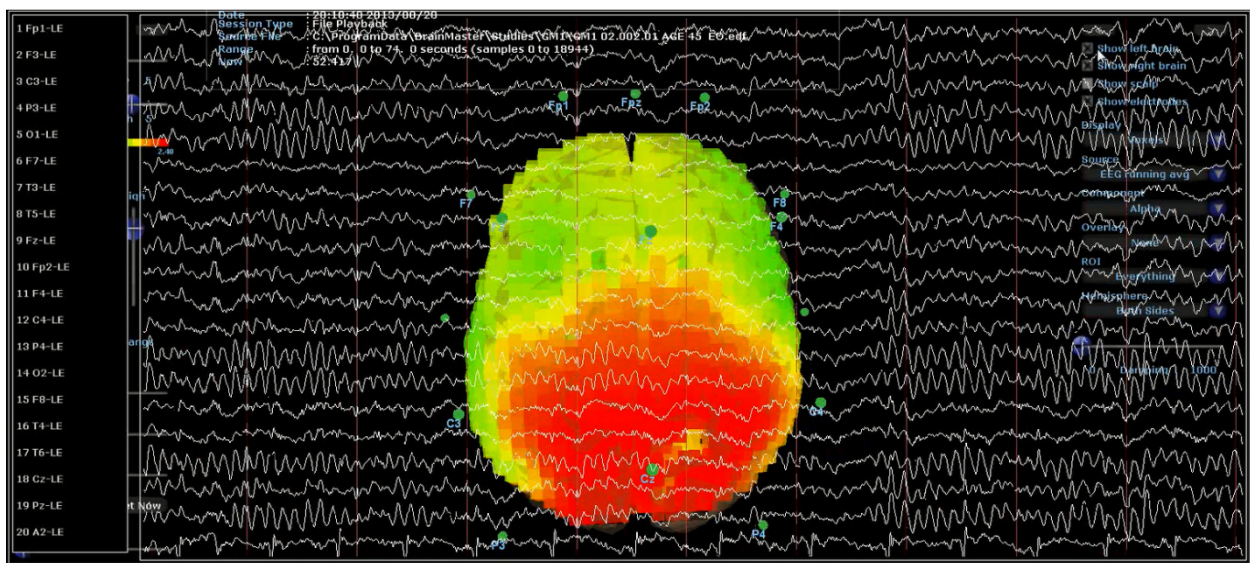


Figure 7 – the same experienced driver, during the post-race condition. This alpha image shows an extreme degree of relaxation, the presence of post-stimulus reinforcement (PRS), a state of brain reward and rest.

### Kaz - An Endurance Driver

Kaz is an endurance driver. He is also professional, but he does not do the type of precision, highly variable work that Craig does. His specialty is endurance races, which can last for 24 hours, and which require a team of drivers. Kaz can drive for up to 8 hours, without undue fatigue, and while remaining alert yet calm. He showed a uniquely different brain activation while driving. Kaz is able to perform in a sustained fashion, while continually producing significant amounts of alpha. Moreover, his alpha “excess” is relatively frontal. What this suggests is that while he is (remarkably) able to maintain a typical level of alpha relaxation even under task, he is especially “cool” with regard to the anterior cingulate area, shown here in red, indicating extreme relaxation.

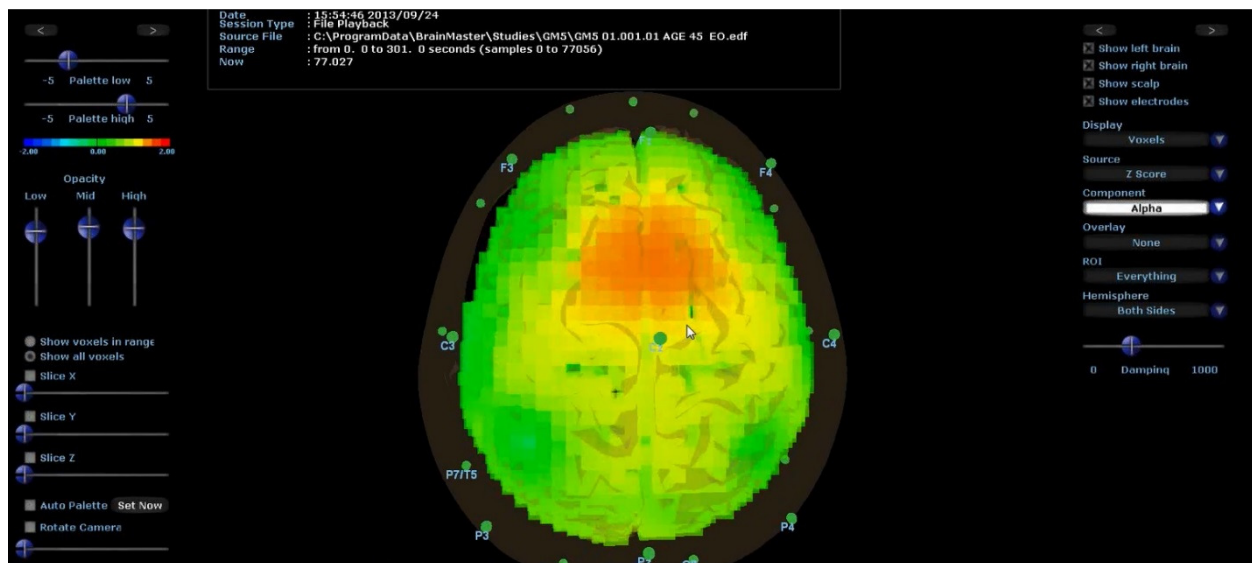


Figure 8 – Kaz’s EEG in alpha during his driving performance. His brain shows a relaxed state that would help facilitate sustained, efficient, automatic performance.

### Kelly – A “fit” Driver

Kelly is a fitness expert and writer who is very influential in promoting physical, mental, and emotional flexibility and strength. She was included in the test group because she has no prior exposure to sports cars, and is far from experienced as a driver. Therefore, her responses were of special interest in comparison to the experienced drivers. During the initial phases of the test

drive, Kelly was very apprehensive, and was unsure what to expect.



Figure 9 – Kelly during the test drive, during a state of apprehension.

Her brain activation pattern reflects this, and shows an increased amount of activation in the right dorsolateral frontal cortex, the brain location involved in looking for and responding to patterns that indicate possible danger.

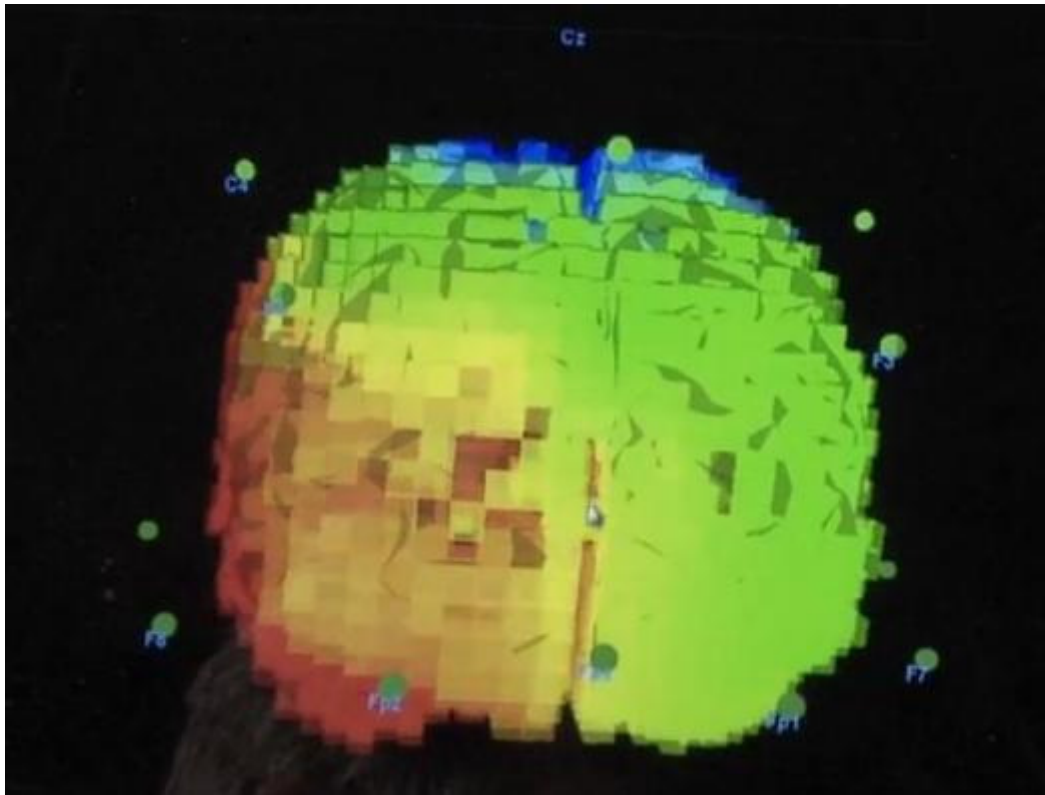


Figure 10 – Kelly’s apprehensive brain signature – activation of the right dorsolateral frontal cortex, associated with looking for danger.



Figure 11 – later in the drive, Kelly became more relaxed.

Kelly’s report of being relaxed is confirmed by the EEG image concurrent with the completion of her drive. The prominent gamma activity that was seen in her right frontal area is now gone, indicating that her fear reaction has subsided.

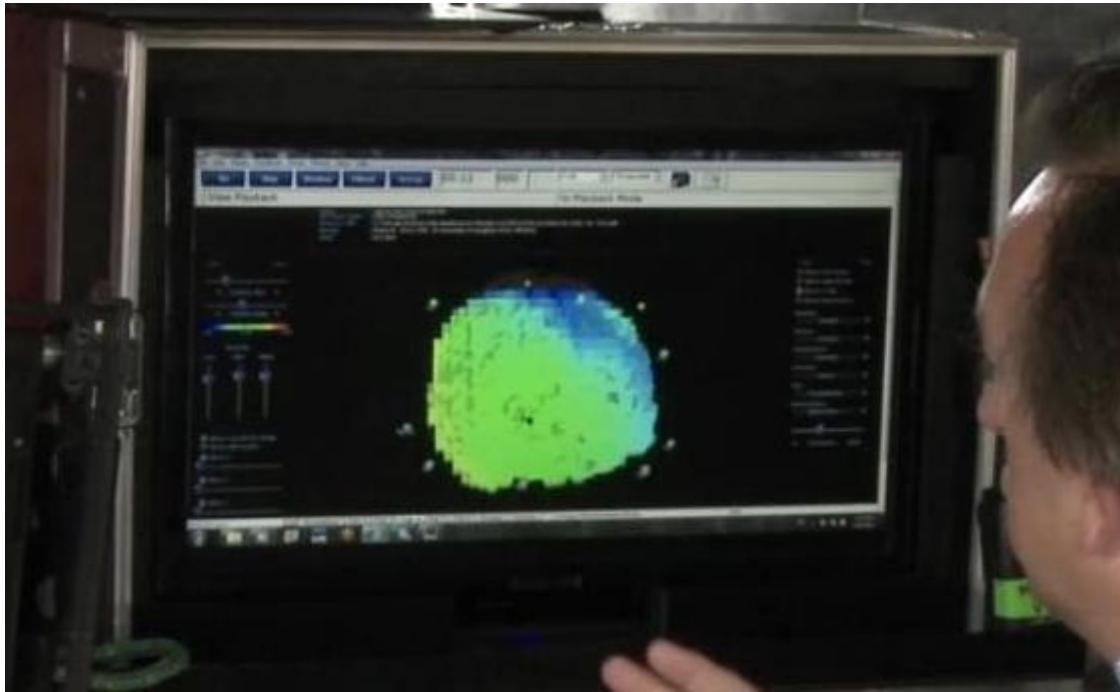


Figure 12 – Kelly’s relaxed brain image, showing the reduction to normal levels of the right frontal activation. Kelly is no longer looking for danger, and is more confident.

A remarkable observation was then made, at the conclusion of the test drive. As Kelly completed the track, and was finishing her last stretch into the finish line, her pattern took on a distinctive form. There was a strong activation of alpha in the right hemisphere, indicating that the fear mechanism was being relaxed, and taken off line. At the same time, there emerged an activation of the sensorimotor cortex, indicated by a localized suppression of alpha. What this latter observation implied can be best understood by referring to Barry Serman’s original work with cats, and also with high-performance fighter jet pilots. Serman interpreted the presence of alpha or SMR in these regions as an indication of the “intention not to move.” Because we see the opposite in this case, it could be inferred that Kelly does not have the intention to remain still, but rather, has the intention to continue moving. This was related to the staff, as Kelly came into the finish line. When asked immediately after stopping, how she felt, she replied, “I want to keep going.” This was a direct confirmation of the EEG observation, which confirmed that at that moment, Kelly wanted to continue, and had no intention of stopping. At that point in time, jaws dropped, as the staff indicated that they thought the EEG machine was somehow reading

peoples' minds. However, this was a simple application of a simple principle. The relative activation of a particular brain region can be used to infer the current state, and/or intentions of an individual. The use of live EEG-based brain imaging is thus not limited to clinical or disease situations, but is also applicable for cases in which mental challenge, mental fitness, and mental performance are involved, and healthy and high-functioning individuals are being assessed.

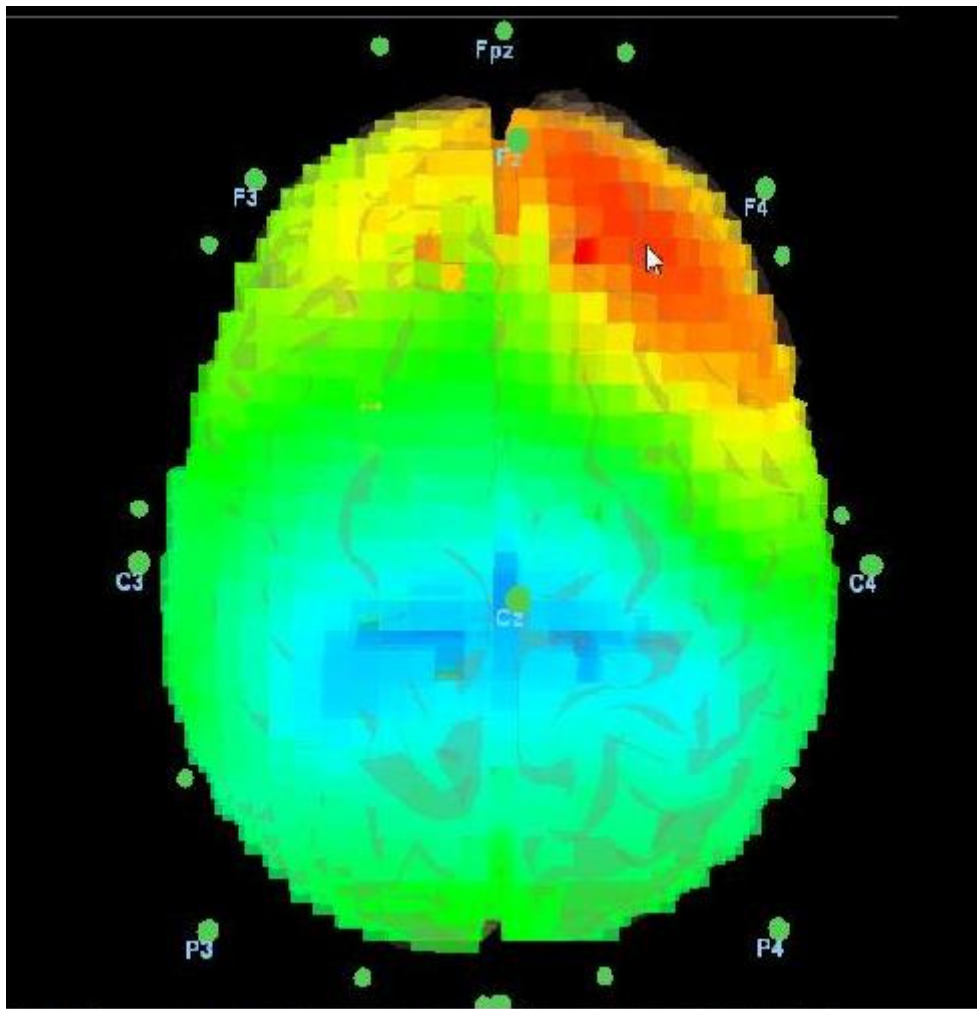


Figure 13 – Kelly at the end of the driving trial. Her state of alpha shows that her motor area is primed for action, while her right frontal lobe is in a relaxed state. This reflects the intention not to move, or as she put it, to “keep going.”

#### Evan – A “scanning” Driver

Evan is a professional business analyst and blogger, who is interested in technology, but is not an experienced performance driver. His approach to the driving experience was one of being very

alert and interactive, and by his own report he was not very relaxed. His images show his individual pattern of activation, during the times of the drive. By looking at a set of surface maps, for example, it is clear that, while he is not agitated or dysregulated in any way, he does have somewhat lower alpha than expected, plus interesting “pockets” of gamma activation.

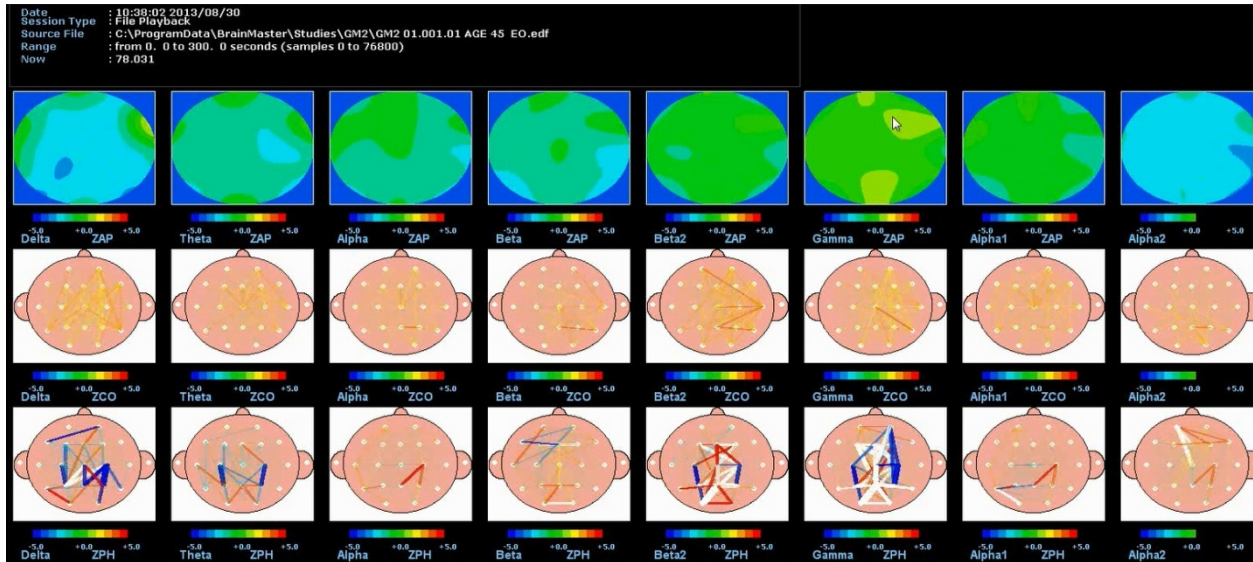


Figure 14 – Evan’s surface maps at the beginning of the trial. He is activated, with a deficit of the typical alpha waves of relaxation, and also with localized gamma activation in the poster cingulate area, and also in the right frontal areas. He is scanning the environment, looking for possible hazards.

His 3-D image in alpha shows a distinct reduction in alpha in the left frontal region. This indicates that the serial scanning process involved in determining safety and “approach” behavior is particularly activated. He is thus working through many scenarios and possibilities, ensuring that everything that could be a problem has been thought about beforehand. It is with this left frontal activation pattern that he facilitates the ability to ensure that it is safe to proceed with the unfamiliar, and potentially hazardous, new task.



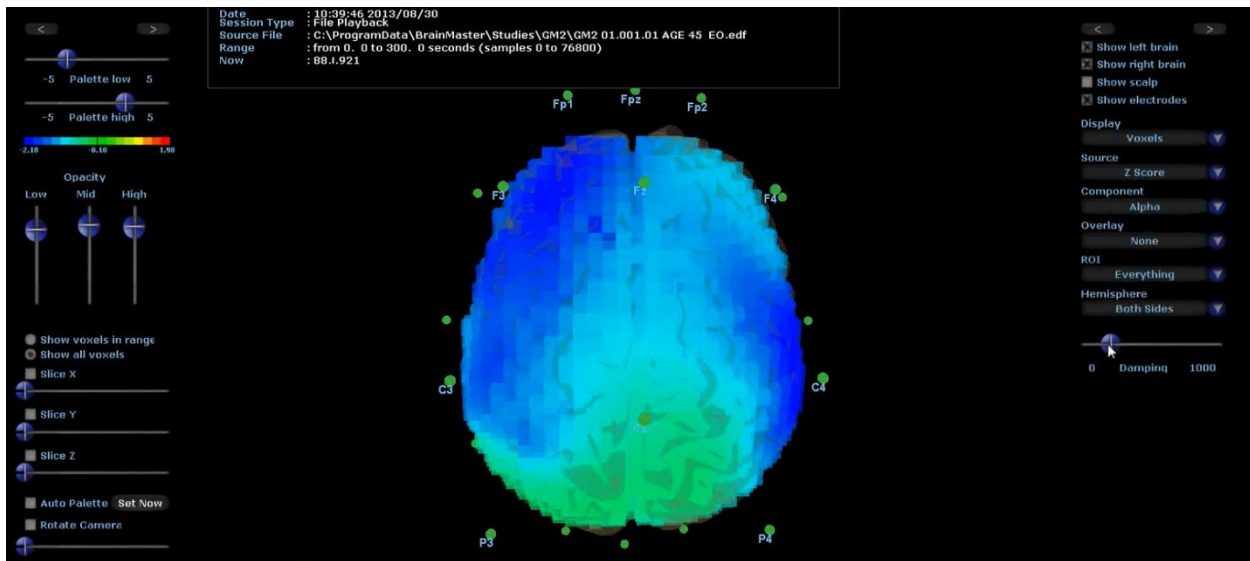


Figure 15 – Evan’s alpha pattern, showing a reduction in alpha, associated with his being activated and alert.

Evan, scanning behavior is accompanied by a unique activation in gamma:

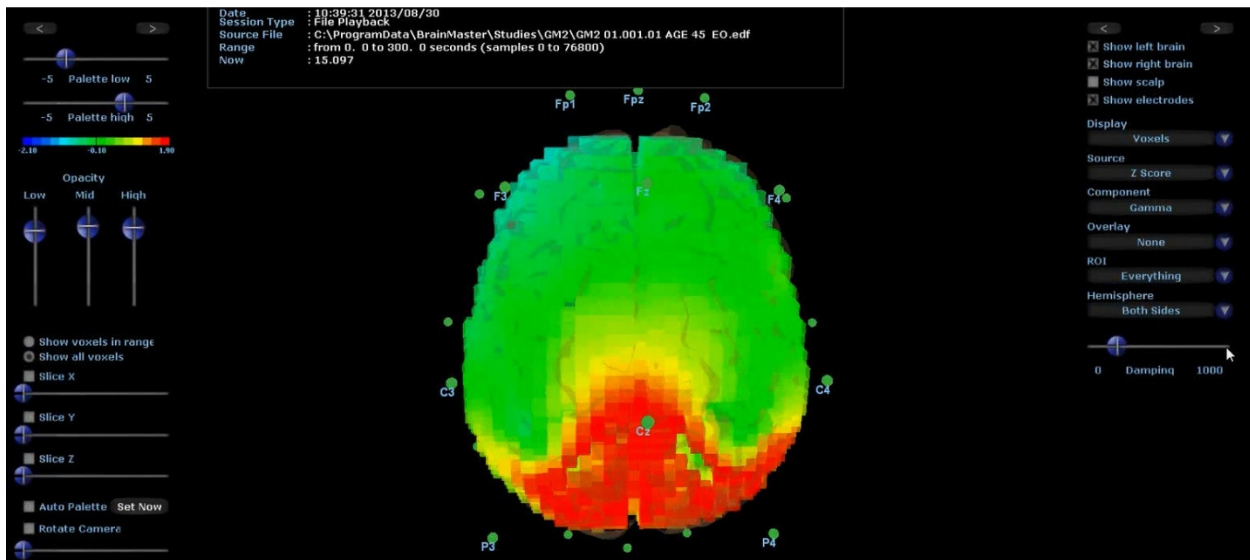


Figure 16 – Evan’s gamma image at the beginning of the drive. He is very active, scanning visually and using the posterior cingulate area to integrate input.

Evan, due to his individual style, and his efforts to manage the difficult situation he has been placed in, goes into a clear state of scanning, searching for evidence that it is safe. The involvement of the visual system, and the posterior cingulate gyrus, as shown, indicate that the mechanisms responsible for rapid input of visual information, plus the ability to quickly switch attention, are very active at this time. This facilitates a connection to the outside world, similar to that of Craig. However, in Evan, there is no evidence of a direct interaction with the visual

cortex and the motor cortex. Rather, his brain is still in a mode of focusing resources on what to pay attention to, which is a less automatic process. Even does not have the benefit of thousands of hours behind the wheel, upon which to draw.

A Sufi - Extreme ability to control (or tolerate) pain.

The following example of extreme functional capability is an individual who is able to demonstrate the ability to control, or to tolerate, pain through mental (and spiritual) discipline. (Collura, Hall, Peper, & Booiman, 2014)

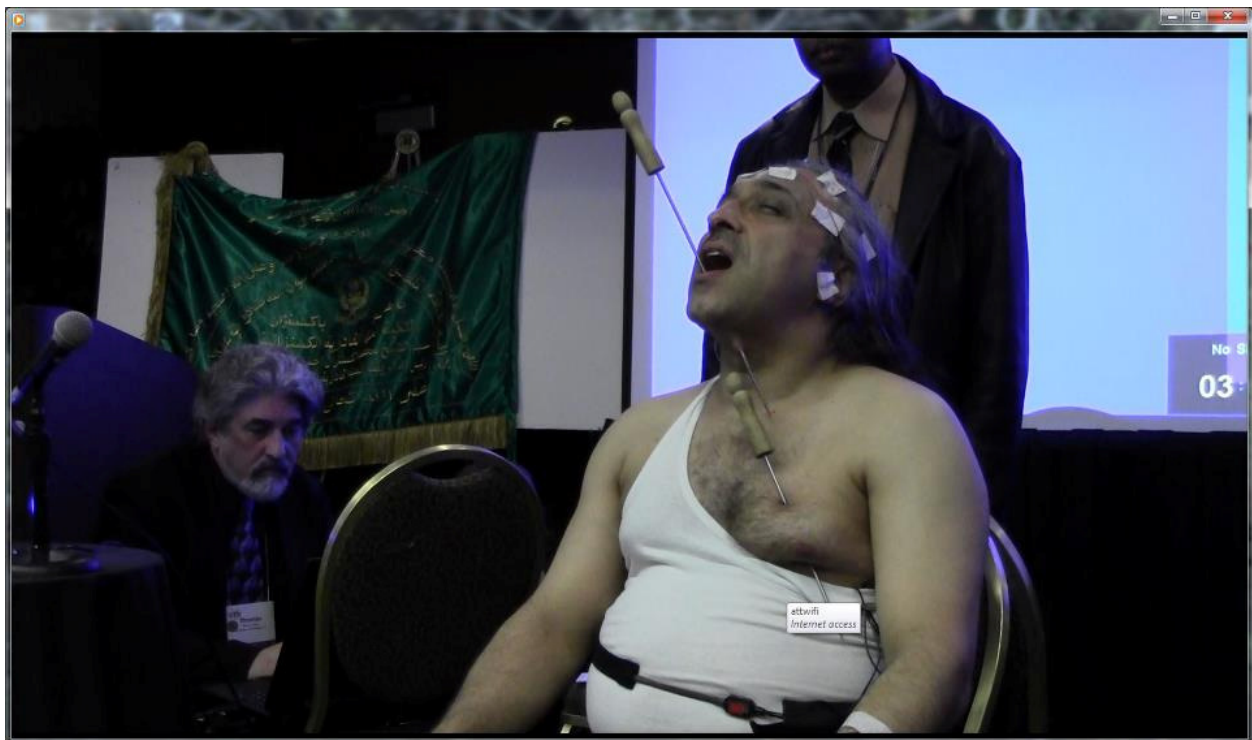

Figure 17 – the Sufi has pierced himself, and is demonstrating his ability to tolerate what a typical person would find a traumatic and injurious experience.

During this piercing procedure, analysis of his QEEG live map revealed a significant de-activation (“deficiency”?) in specific brain regions. These appear to be pockets of inactivity, embedded in a generally typical amount of gamma. They can be thought of as depressions, within which relatively little neuronal activity is occurring.

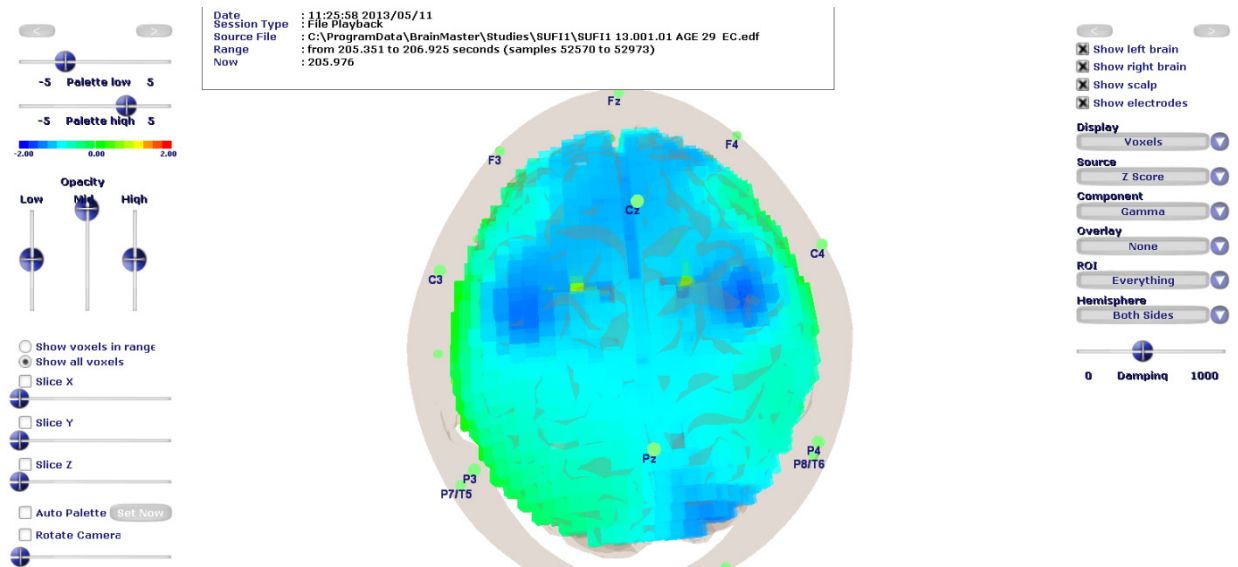


Figure 18 – the Sufi’s pattern of gamma shows pockets of de-activation, which appear prominent in the primary visual, sensorimotor, and mesial frontal areas.

Another way to view this is to consider only those areas that are inactive. In other words, set the display so that areas that are typical, or even somewhat below typical, are not seen at all. Then, the image that will emerge would specify the areas of inactivity in precise locations. When the imaging parameters are adjusted to show only the areas that are de-activated, a different and more revealing view thus emerges:

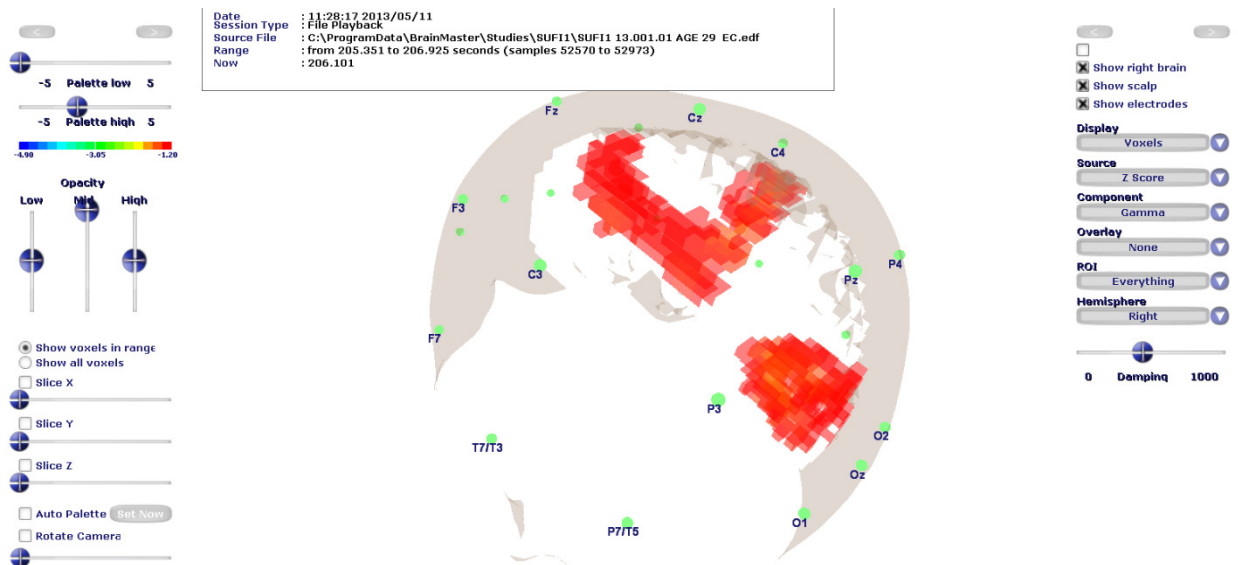


Figure 19 – the Sufi’s pattern of gamma activation, at low z-scores, showing areas that are not active. A hub or network that subserves awareness has been shut down. This network includes primary visual, somatosensory, cingulate, and insular areas.

### Clinical Example – Elderly with Speech Deficit

The following example is from an elderly individual, who had moderate speech difficulties. Slow speech and word grasping were evident. When recorded an imaged in beta, his EEG shows a deficit of beta that is focused on Broca’s area. This area resides in front of the facial motor control regions, and manages verbal speech. This deficit correlates directly with the functional deficit in this individual.

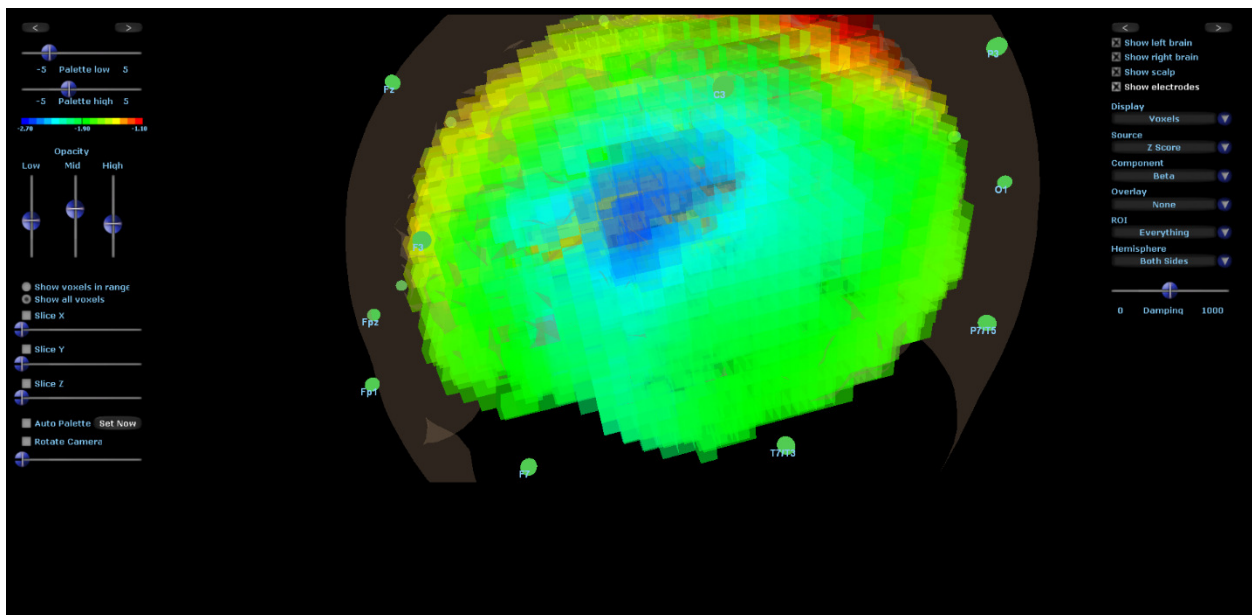


Figure 20 – gamma activation image of an elderly individual with speech difficulty, illustrating the localized de-activation of Broca’s area.

### Case Example – Executive Function Deficit

The following example shows a deficit in activation in a client who presented with difficulties with attention and motivation. At the age of 33, she continued to live at home, did not drive, and was not able to hold a paying job. In her imaging analysis, a deficit in beta was found. This deficit is shown in the surface maps as a diffuse reduction that is most profound in the beta band.

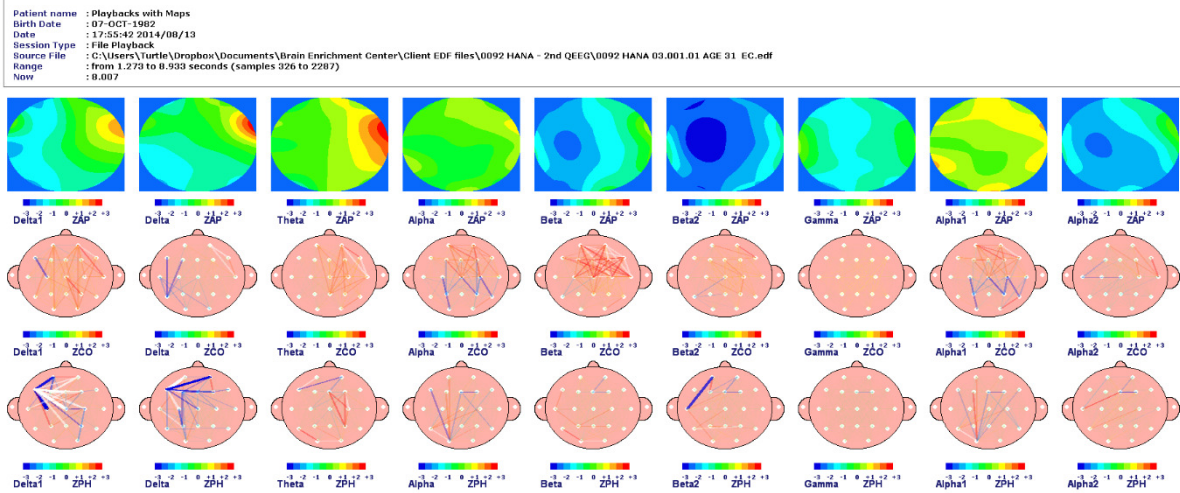


Figure 21 – surface maps showing diffuse deficits of beta and alpha, as well as a focal excess of slow waves.

When the EEG is further imaged, the location of the deficit is more accurately determined. IN this case, it is the anterior cingulate gyrus that is involved in the deficit:

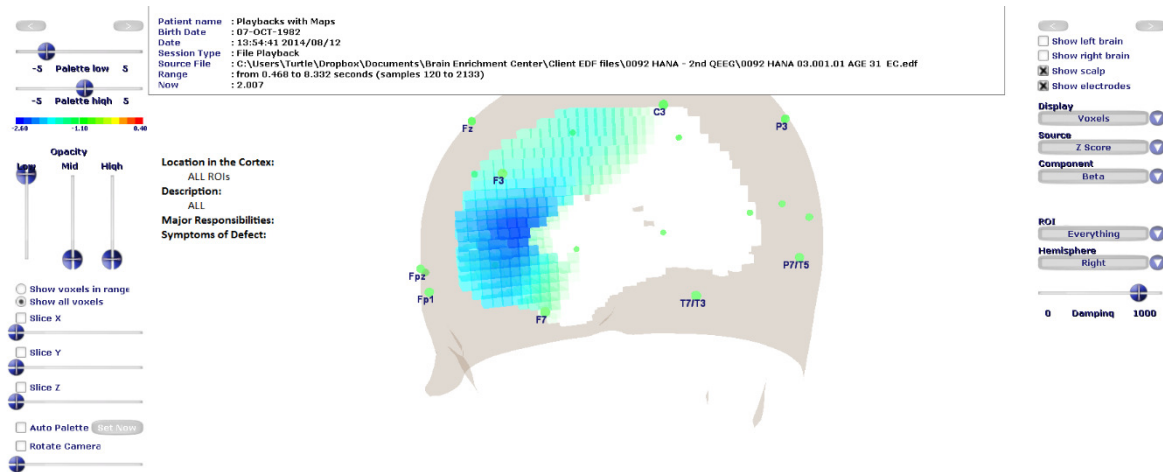


Figure 22 – Z-score image of beta at low levels. A focal deficit of activation is clearly evident in the anterior cingulate gyrus

When viewed from the top, the image further shows that the deficit includes not only the frontal pole, but also the right somatosensory cortex.

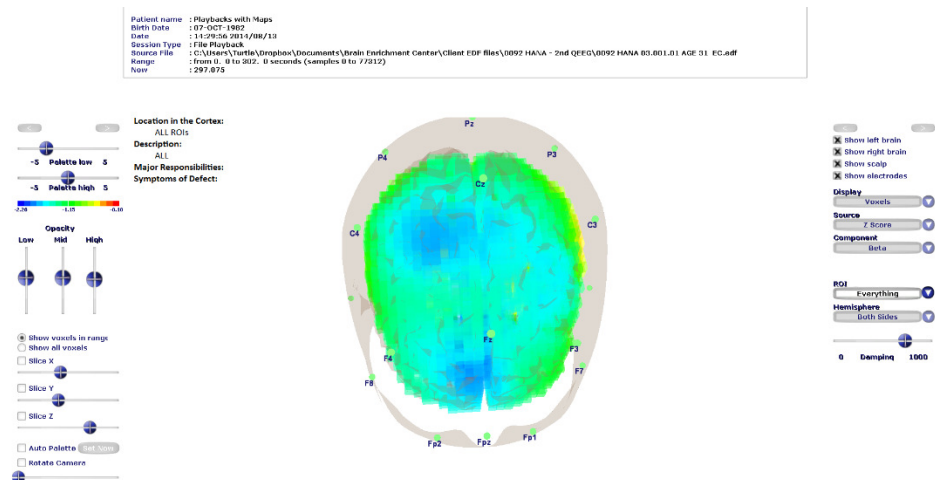


Figure 23 – the deficits of beta are seen to include the right mesial prefrontal area, and also the right occipito-parietal sensory integration areas.

### Case Example – Eating Disorder

The following example shows the frontal activation patterns in gamma for an individual who was being evaluated for a performance enhancement program. This was an accomplished coach and teacher, who had won national awards for coaching, at the professional level. This client was viewing a variety of probe words, related to physical fitness and personal preferences. The response to “Body Fat” was expected, which was a notable but not extreme negative reaction, indicating that this person did not like the idea of body fat.

The word “Obese People,” however, elicited an extremely negative response. The participant, when asked, stated that she did not have a particular problem with that concept. Quite simply, “people should not be obese.” However, the investigator questioned further, insisting that there must be something she was not revealing. Finally, after further prodding, she began to cry, and blurted out, “I used to be obese.” She then described the humiliation and pain she endured, and that she had vowed to never be obese again. She further divulged that she had an eating disorder, and that she was hiding that fact. This was a breakthrough that had not been forthcoming, and was based on the availability of the live EEG imaging, to show her actual emotional response.

What emerged during this test was an unanticipated benefit of having brain activation data in conjunction with written or verbal report. It becomes possible to determine how well a subject’s own report of emotional and decision-making responses correlates with the brain activity associated with each thought, feeling, or action. EEG imaging provides instantaneous data related to the underlying brain activity which precedes thinking, feeling, or acting. The brain

circuits that are involved with these processes, particularly in the frontal lobes, and in the cingulate gyrus in particular, are revealed through the images that show which areas are active or at rest.

Generally, this type of example shows that EEG imaging can be of value in a general counseling or psychotherapeutic setting. While this is not specifically a “lie detector,” it is an emotional response indicator that provides immediate data. It is important to note that, since this system responds within 30 milliseconds to brain activity, the visible data precedes the individual’s conscious awareness, and is thus a preconscious measure.

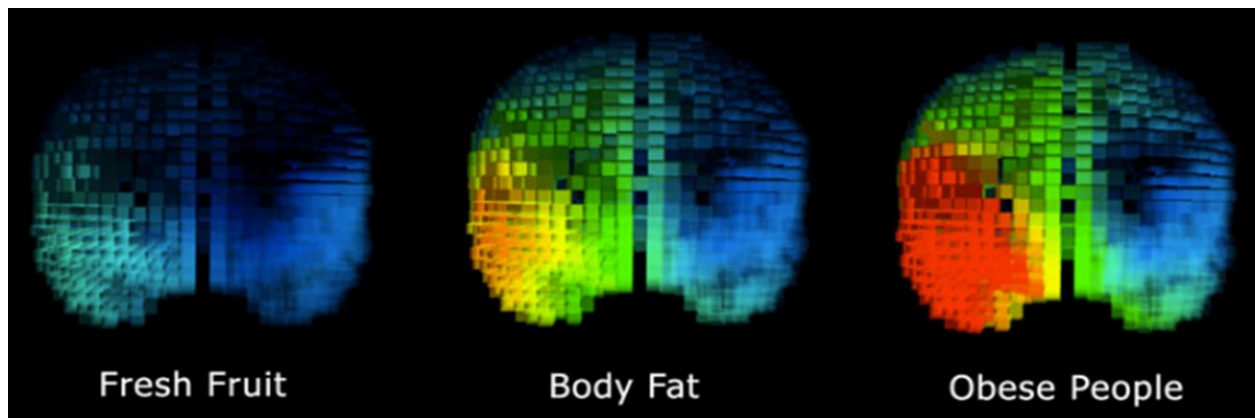


Figure 24 – event-related word responses of an individual who was subsequently found to have an eating disorder. The abnormally large negative response to the words “Obese People” is clearly evident.

#### Neurobiofeedack Imaging and Emotional Decision-Making

The following figure shows the brain locations that are particularly relevant to decision-making, as indicated in current research (e.g. Davidson & Begley, 2012), and also by the examples shown here. There are two main areas of each frontal lobe. The medial portions are responsible for primary types of emotional responses (“sensation”), before information is more fully integrated and processed. The dorsolateral areas perform more integrated emotional “perception,” and even possibly more advanced emotional “comprehension.” At any instant, these areas are either relatively active or not, depending on the individual’s experiences, as well as personal style of responding to stimuli.

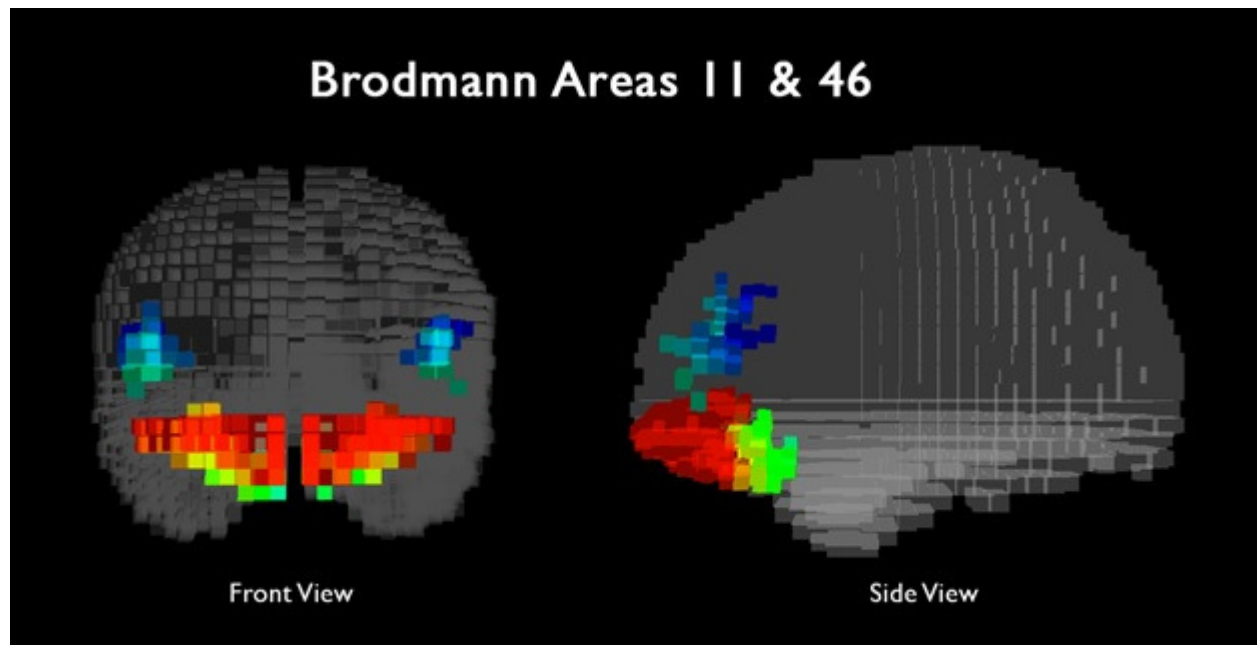


Figure 25 – the two Brodmann areas most involved with emotional decision making are Areas 11 (mesial prefrontal infraorbital cortex) and 46 (dorsolateral frontal cortex)

These brain sites have functions that can be described in terms of a model described by Collura, Zalaquett, Bonstetter, and Chatters (2014). This model associates specific decision-making functions with the left and right frontal lobes, as well as the distinction between primary and secondary evaluation and response mechanisms. When using brain activation data such as we have seen, this model allows one to interpret individual thoughts, feelings, and actions in terms of which portions of the model are active at any given time.



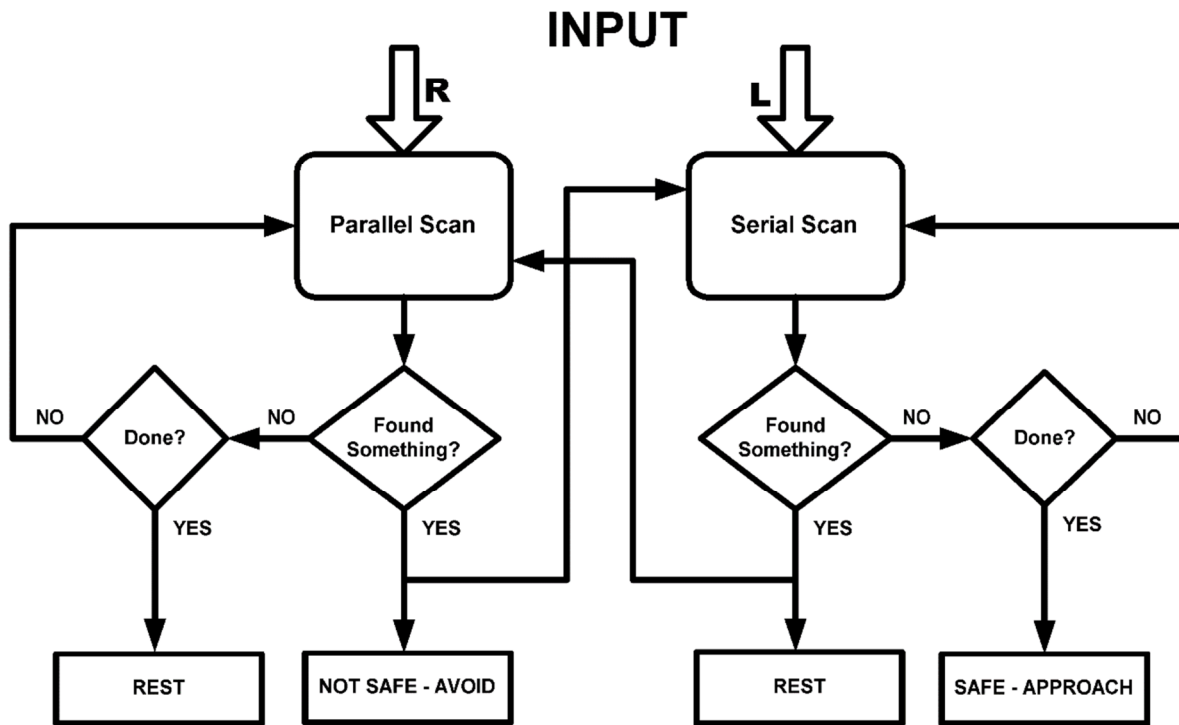


Figure 26 – model for emotional decision-making based upon frontal lobe function

As an example of a maladaptive state that can occur within this model, the following shows the predominant response mechanism of someone who is avoidant or paranoid:

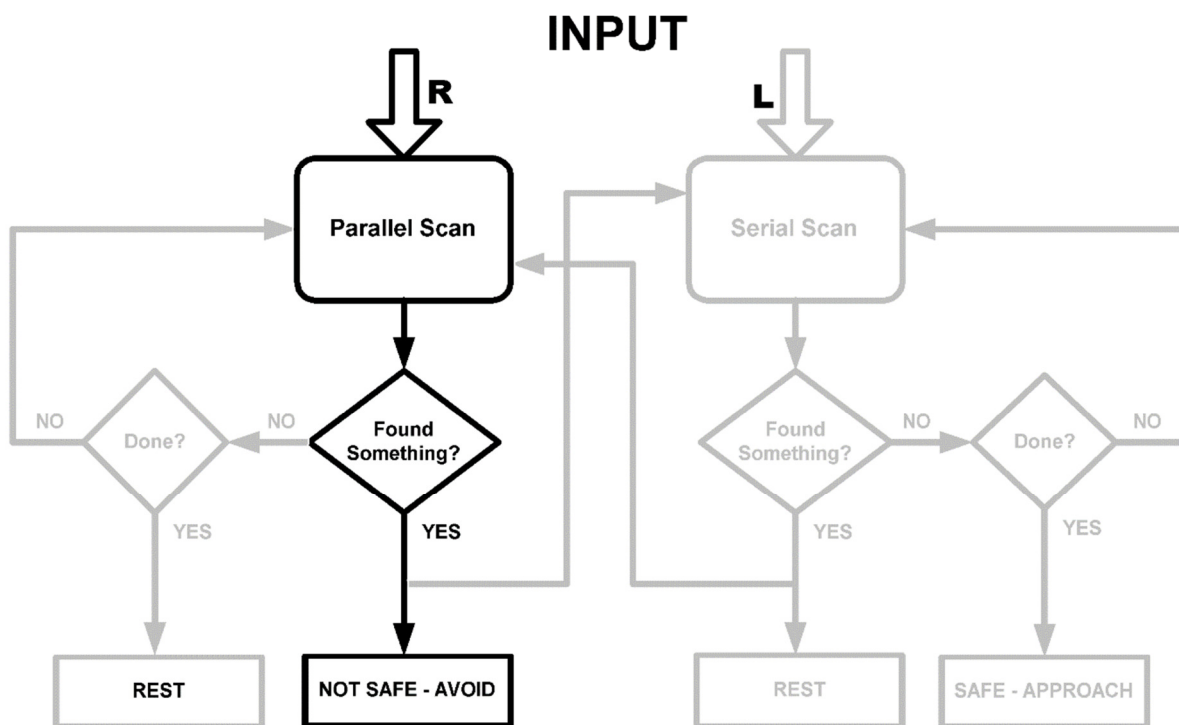


Figure 27 – selective activation pattern that would result in avoidant emotion, thoughts, and behavior.

As an alternative, an individual who might be characterized as a risk-taker, would have the following dominant mechanism:

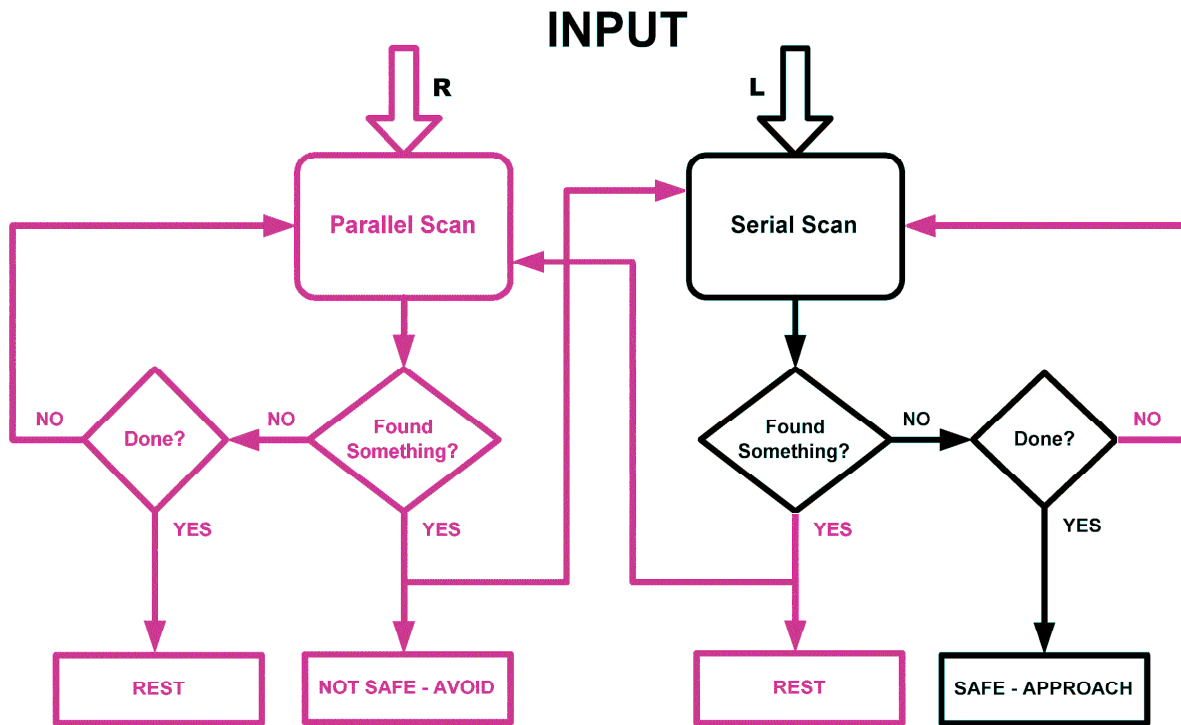
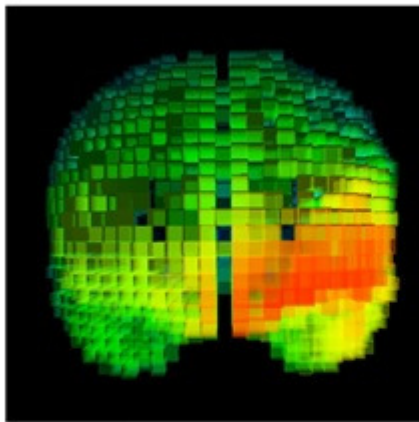


Figure 28 – pattern that would associate with risk-taking or uninhibited behavior.


As another example of EEG-based brain activation imaging, and in view of this model, the following shows different responses to foreign languages. In this example, a subject was exposed to languages including her native language, and 3 secondary languages that she understood. She showed the maximum positive response to her native language (Spanish), a relatively neutral response to English, a moderately positive response to French, and a strong and complex response to German. This was consistent with the fact that she was more comfortable with languages like her own, and found German difficult and requiring effort to understand.

## Target Training International - Language Study Results

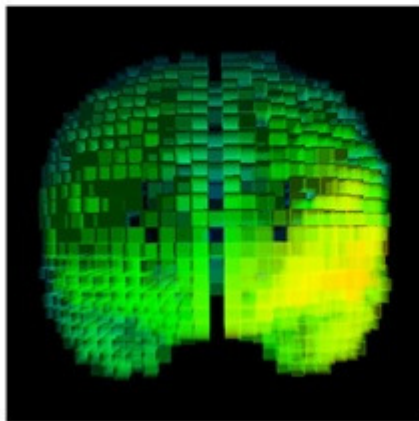
### Data Sample: Enthusiastic



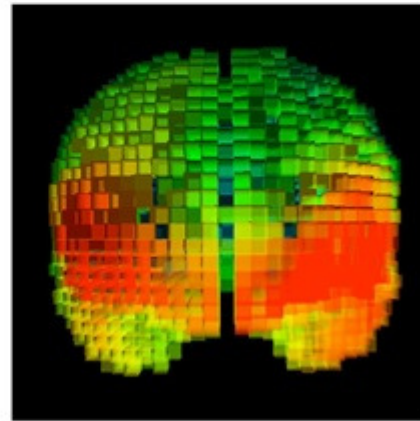
**Spanish**  
(1st Language)



**English**  
(2nd Language)



**French**  
(3rd Language)



**German**  
(4th Language)

Figure 29 – emotional reactions to listening to a foreign language.

High-speed imaging is also possible. In the following examples, an individual was presented with words relevant to a serious criminal incident. The probe words were meaningful to the subject, and elicited specific reactions in brief intervals following the words presented. The client evidently had very different responses to words referring to an employer, family members, or activities. By comparing these responses with the individual’s verbal report, it was possible to confirm that he was providing consistent information, and that there was no evidence of his attempting to deceive the investigators. While this was not a “lie detector” per se, it was nevertheless a way to observe and quantify an emotional response, and to correlate it with specific related information. This would appear to provide a valuable new tool for not only forensic, but also for related event-related emotional assessment and therapy.

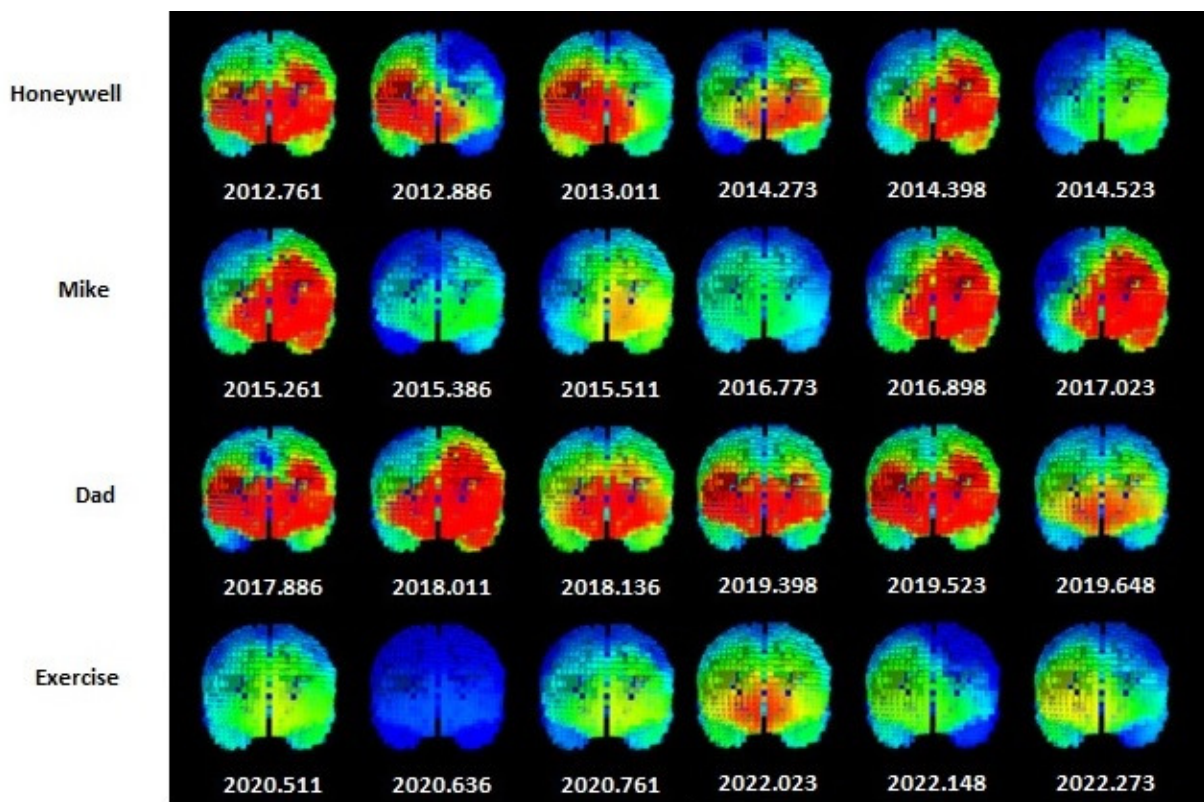


Figure 30 – event-related responses to words presented to a subject under investigation for a crime. The probe words show different sequences of emotional activity, across time. The speed of these images is 8 per second, so each image reflects 1/8 of a second of brain activity.

## Summary

This report has summarized how new methods in EEG-based brain imaging (“Neurobiofeedback Imaging”) can be used in many different ways. By revealing brain activation data in real time in the form of high-speed images, it now becomes possible to see what is happening in a brain as it happens. This approach is also surprisingly accurate and cost-effective, especially when compared to other methods. These examples should help to demonstrate the value of live EEG-based brain imaging, and to encourage mental health practitioners and researchers to consider incorporating it into their work.

## References

Bonnstetter, R., Bonnstetter, B., Hebets, D., & Collura, T. (2012) This is your brain on language.

Bonnstetter, R.J., Collura, T.F., Bonnstetter, B., & Hebets, D. (2012) Trait & state-based depression indicators measured using real-time sLORETA imaging and quantification. Presented at the International Pharmacology-EEG Group, New York, New York.

Collura, T.F. (2009) Neuronal Dynamics in Relation to Normative Electroencephalography Assessment and Training, *Biofeedback* Volume 36, Issue 4, pp. 134-139.

Collura, T.F., Guan, J., Tarrant, J., Bailey, J., and Starr, F. (2010) EEG Biofeedback Case Studies Using Live Z-Score Training (LZT) and a Normative Database, *Journal of Neurotherapy* 14(2), 22-46.

Collura, T.F., Hall, H., Peper, E., Booiman, A. (2014) A Sufi self-piercing analyzed with EEG and sLORETA imaging. Annual Meeting of the Association for Applied Psychophysiology & Biofeedback.

Collura, T.F., Thatcher, R.W., Smith, M.L., Lambos, W.A., and C.R. Stark (2009) EEG Biofeedback training using Z-scores and a normative database, in: (Evans, W., Budzynski, T., Budzynski, H., and A. Arbanal, eds) *Introduction to QEEG and Neurofeedback : Advanced Theory and Applications*, Second Edition. New York: Elsevier.

Collura, T.F., Zalaquett, C., Bonnstetter, R., & Chatters, S. (2014) Towards an operational model of decision making, emotional regulation and mental health impact. *Advances in Mind-Body Medicine*, in press.

Davidson, R. & Begley, S. (2012) *The Emotional Life of Your Brain*. New York: Hudson Street Press.

Ikeda, C. & Kirino, E. (2004) Combined fMRI and LORETA study of illusory contour perception in schizophrenia. *Frontiers in Human Brain Topology*, 1270, 356-360.

John ER, Prichep LS, Easton P. (1987) Normative data banks and Neurometrics: Basic concepts, methods and results of norm construction. In: Gevins AS, Remond A, eds. Handbook of Electroencephalography and Clinical Neurophysiology, Vol. I. Amsterdam: Elsevier: 449-95.

Lubar, J.F. (1997) Neocortical dynamics: implications for understanding the role of neurofeedback and related techniques for the enhancement of attention, Applied Psychophysiology and Biofeedback, 22, 111-126.

Pascual-Marqui, R.D. (2002) Standardized low-resolution brain electromagnetic tomography (sLORETA): technical details. Methods and findings in Experimental and Clinical Pharmacology, 24:5-12.

Sanders, L. (2014) Busy neurons don't always draw blood. Science News August 12, retrieved from <https://www.sciencenews.org/article/busy-neurons-don't-always-draw-blood/>

Sterman, M.B. (1996) Physiological origins and functional correlates of EEG rhythmic activities: implications for self-regulation. Biofeedback and Self-regulation, 21(1), 3-33. Sterman, Kaiser. Simulated visuomotor task

Sterman, M.B., Mann, C.A., Kaiser, D.A., and B.Y. Suyenobu, "Multiband topographic EEG analysis of a simulated visuomotor aviation task," Int'l Jour. of Psychophysiology, 16(1994) 49-56.

Walker, J.E., Kozlowski, G.P., and Lawson, R. (2007) A modular activation/coherence approach to evaluating clinical/QEEG correlations, Journal of Neurotherapy 11(1) 25-44.

Xiaoxiao, B., Towle, V.L., He, E.J., & He, B. (2007) Evaluation of cortical current density imaging methods using intracranial electrocorticograms and function MRI. Neurimage 35(2), 598-608.